

# A SUCCESSFUL TREATMENT OF TARSAI TUNNEL SYNDROME USING HYDRO-DISSECTION TECHNIQUE: A CASE REPORT

**Aziz MA<sup>1,2</sup>, Puji A<sup>1</sup>, and Tahir SH<sup>1</sup>.**

<sup>1</sup>Arthroscopic Surgery and Sports Injury Unit, Orthopedic Department, Hospital Kuala Lumpur, 50586 Kuala Lumpur, Malaysia

<sup>2</sup>Sports Medicine Department, University Malaya Medical Centre, Jln Profesor Diraja Ungku Aziz, Lembah Pantai, 59100 Kuala Lumpur, Malaysia

## **Correspondence:**

Mohamad Azwan Aziz,  
Sports Medicine Department,  
University Malaya Medical Centre  
59100 Kuala Lumpur, Malaysia  
Email: [letsgetfitdrazwan@gmail.com](mailto:letsgetfitdrazwan@gmail.com)

## **Abstract**

Tarsal tunnel syndrome (TTS) is an uncommon musculoskeletal ankle disorder caused by compression of the posterior tibial nerve at the tarsal tunnel level. Our objective is to describe the first case report of tarsal tunnel syndrome successfully treated with the hydro-dissection technique. This is a case of 41 years old lady who suffered from severe ankle sprain. She was prescribed an ankle brace to treat her ankle sprain. After 1-year post-injury, she complained of moderate to severe medial ankle pain, neuropathic, radiating to the big toe. Clinical assessments revealed tenderness at the tarsal tunnel area, accompanied by a positive Tinel sign, reproducing similar symptoms. Ultrasound examination confirmed an enlarged posterior tibial nerve at the level of the tarsal tunnel, with tenderness during sono-palpation and reproducing symptoms on sono-Tinel sign. She underwent hydro-dissection of the posterior tibial nerve with a marked reduction in pain and improvement in daily function.

**Keywords:** Tarsal Tunnel Syndrome, Neuropathic Pain, Chronic Pain, Hydro-Dissection, Entrapment

## **Introduction**

Tarsal tunnel syndrome (TTS), a rare musculoskeletal disorder, is often underdiagnosed due to diverse available diagnoses of medial-sided ankle pain, leading to a low prevalence of the disease (1, 2). Keck, in 1962, was the first person to describe TTS as a compressive peripheral neuropathy of the posterior tibial nerve below the flexor retinaculum (3). Diverse etiological factors for tarsal tunnel syndrome. External factors include tight shoes, trauma, and post-surgical scare. Internal factors include diabetes mellitus, osteophyte and ganglion cysts (4). To the author's knowledge, there is no literature that describes the utilization of the hydro-dissection technique in the management of tarsal tunnel syndrome. We reported a TTS case following prolonged bracing, with significant improvement after hydro-dissection of the posterior tibial nerve.

## **Case report**

This is a case of a 41-year-old lady who had a right ankle inversion injury following a trip and fall. Immediately after the fall, she developed severe pain over the right lateral

ankle, associated with gross swelling and bruises over the lateral ankle. She visited the emergency department, had an ankle X-ray, which was reported as normal and was discharged with painkillers. She was treated with ice therapy, bandage, and partial weight bearing with crutches. Following the injury, she developed severe lateral ankle pain on and off, recurrent swelling on prolonged weight-bearing activities, and instability of the flat surface. Clinical examination revealed marked tenderness at the anterior talofibular ligament (ATFL) area, calcaneofibular ligament (CFL), deltoid ligament, and peroneal tendon. She also demonstrated a marked tenderness in the talar dome area. The anterior drawer test had a firm endpoint, and the talar tilt test was positive. Magnetic resonance imaging (MRI) of the right ankle demonstrated a chronic tear of ATFL and CFL. The chondral cartilage of the talar dome was preserved. In view of instability and recurrence swelling, she was advised for a stirrup ankle brace to promote healing of the ATFL and CFL area and treat her instability while on physiotherapy.

Unfortunately, she missed her follow-up as she suffered from myocardial infarction, complicated by euglycemic diabetic ketoacidosis, and her appointment was postponed

multiple times due to the COVID-19 pandemic. Thus, she was on a prolonged brace, and she wore it most of the time. She did not get proper treatment from physiotherapy due to her default appointment. After 1-year post-injury, her right lateral ankle pain improved, with a pain score of 2-3/10 on prolonged activities. Her instability symptoms also improved. However, she developed medial-sided ankle pain, an electrical type with a burning sensation radiating to the big toe. She denies any numbness around the right foot. The pain is constantly present, with a maximum pain score of 6-7/10, which was aggravated by prolonged walking. There was no recurrent swelling, locking, or instability. She denies any aggravation during jumping or landing.

There were no symptoms of other joint pain, swelling, deformities, skin rashes, or mucosal symptoms to suggest underlying rheumatological disease. There is no numbness in other limbs, weakness, claudication pain, or back pain. Her diabetes was well controlled with insulin, with HBA1C ranging from 5 to 5.4. Clinical signs revealed maximum tenderness at the tarsal tunnel area, similar to her chief complaint. The Tinel sign was positive, which she described as an electrical sensation radiating to the big toe. There was no tenderness at the posterior tibial tendon, and augmentation with resisted ankle inversion elicited no pain. There was no triggering during hallux flexion or pain on resisted big toe flexion to suggest flexor hallucis longus tenosynovitis. The maximum passive plantar flexion for posterior impingement does not elicit pain. The medial arch was preserved. Neurological examination was normal.

A musculoskeletal ultrasound of her right ankle demonstrated an enlarged posterior tibial nerve at the tarsal tunnel area, as in Figure 1, with a circumference of 2.1 cm<sup>2</sup>. Sono-palpation directly above the posterior tibial nerve elicited similar pain, and sono-Tinel elicited a positive test. Dynamic ultrasound demonstrated limited nerve gliding and scar adherence to the soft tissue. There is no tendinopathy or tenosynovitis of the posterior tibial tendon. No ganglion cyst, varicose vein, or osteophyte compresses the posterior tibial tendon. The nerve conduction study was not performed due to the unavailability of the service at our centre.

She was prescribed nerve gliding exercise, with ultrasound therapy for 1 month, and showed no significant improvement. We proceeded with hydro-dissection of the posterior tibial tunnel at the tarsal tunnel. The hydro-dissection technique using the in-plane technique is shown in Figure 2. We used 10 mls of D5% without local anesthetics to hydro-dissect the nerve above the tarsal tunnel. We chose slightly proximal to the tarsal tunnel because the tarsal tunnel is a tight space, and injecting high volume could cause increased pressure on the nerve. The injection was done from the medial to lateral direction, with visualization of the posterior tibial artery and posterior tibial nerve. Care should be given to avoid injection into the posterior tibial artery. The needle tip placement should be at the perineural area of the posterior tibial nerve. A visualization of distension around the perineural area

marked a successful hydro-dissection. Immediately after the procedure, dramatic pain improved from 5 to 1. The patient was advised to home exercise therapy for 5 minutes every 4 hours to avoid swelling, and the patient should observe any sign of infection. We continued the nerve gliding exercise and prescribed methycobalamin to help regenerate the nerve.

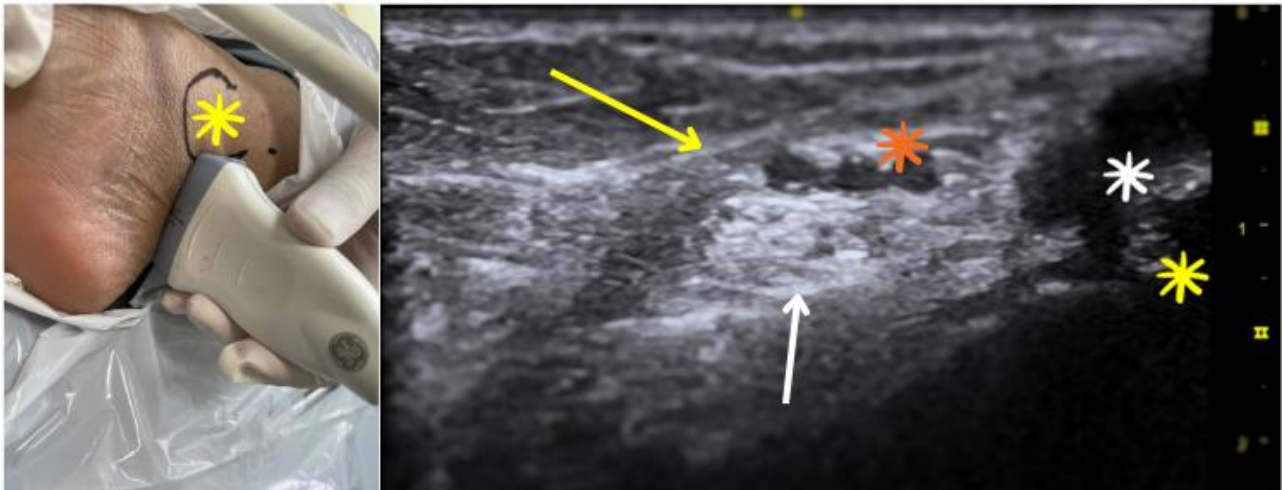
One month and three months after the procedure, the patient reported marked improvement in symptoms, with no recurrent medial ankle pain despite prolonged walking. A follow-up examination revealed an absent Tinel sign and no tenderness in the tarsal tunnel. Repeated musculoskeletal ultrasound demonstrated normalization of nerve size with a circumference of 1.4 cm<sup>2</sup> and normal nerve gliding, comparable to the contralateral limb, as in Figure 3. She also had other multidisciplinary follow-ups to ensure that she received optimal treatment, such as an endocrinologist to control her diabetes and physiotherapy for the usage of physiotherapeutic modalities such as ultrasound.

### Discussion

Literature regarding the TTS is limited. TTS is often underdiagnosed, and the prevalence is low compared to other neuropathies (1, 2). TTS is caused by compression on the posterior tibial nerve below the flexor retinaculum. The posterior tibial nerve is a sciatic nerve branch that travels in the deep posterior compartment into the flexor retinaculum, accompanied by the posterior tibial artery and nerve. The posterior tibial nerve gives terminal branches: medial calcaneal nerve, medial and lateral plantar nerves, above or at the tarsal tunnel. The anatomy of the posterior tibial nerve can be visualized clearly with ultrasound at the tarsal tunnel area, as in Figure 1.

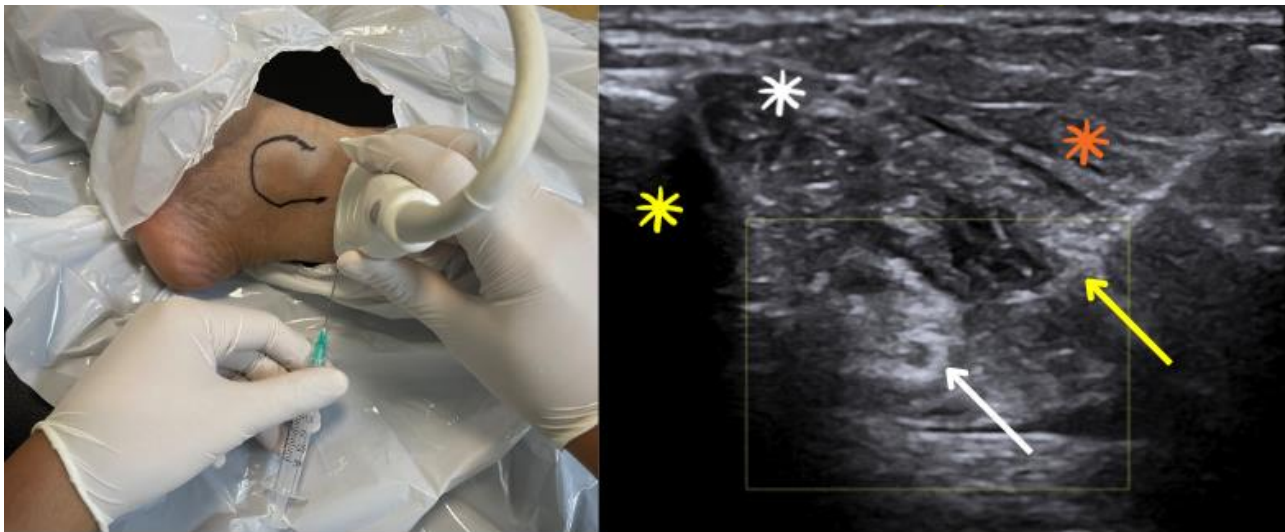
TTS often demonstrates symptoms of neuropathic pain: pain at the medial side, burning, or electrical sensation radiating to the plantar aspect with or without clear neurological deficits. Tinel signs are often positive, indicating a peripheral sensitization with upregulation of nociceptors and ectopic firings at the site of entrapment (4, 5). The dorsiflexion eversion test has been described as a test for TTS, which reproduces pain in 82% of cases (6). A nerve conduction study is an investigation commonly performed in a clinical setting (6). However, the test remains questionable as the sensitivity and specificity of the test remain low.

MRI has been used to identify the soft tissue compression on the posterior tibial nerve. Frey and Kerr examined the role of MRI in TTS and reported that relevant pathology in the tarsal tunnel was identified in 88% of symptomatic cases (7). With the recent advancement, the role of the point-of-care ultrasound is emerging, and it has an important role in diagnosing TTS or another compressive neuropathy. Ultrasound is based on real-time examination, with the ability to assess static and dynamic structures, and is cost-effective. Positive Sono-Tinel sign suggests



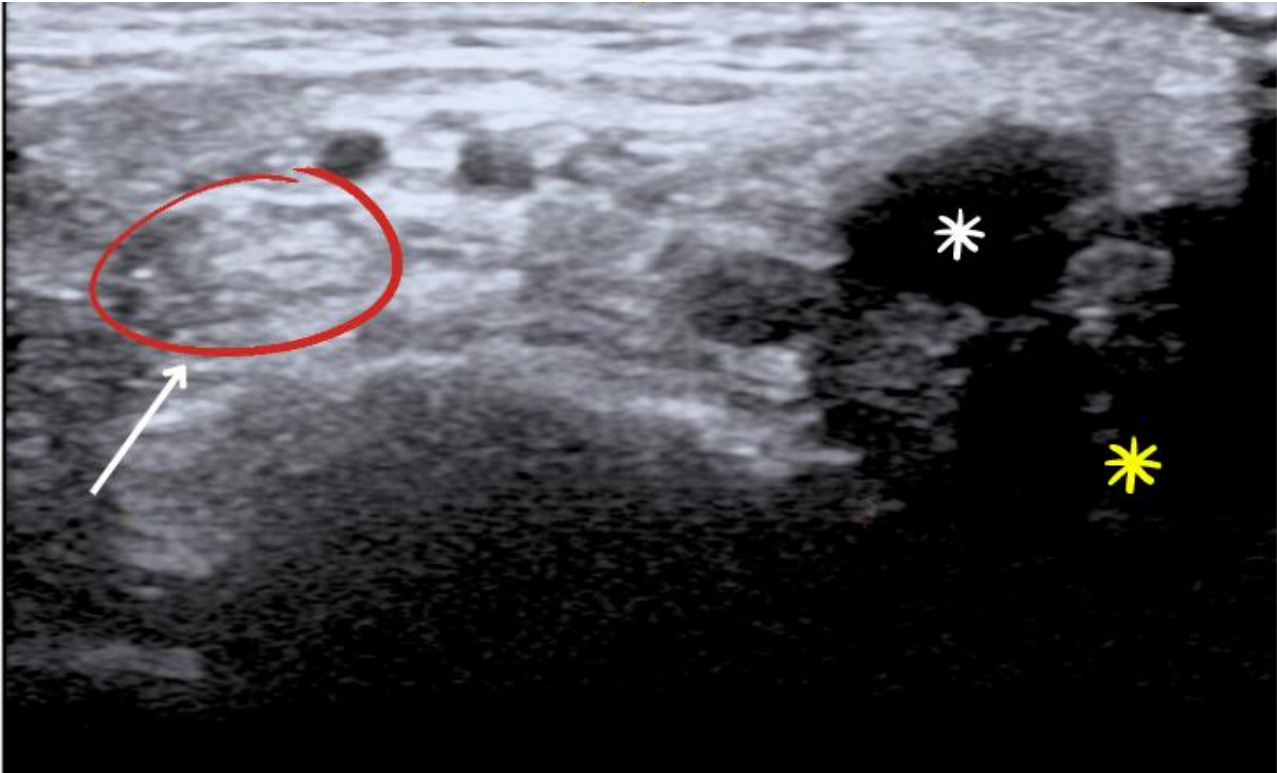
**Figure 1:** This is a short axis view of tarsal tunnel. Probe placement was placed at medial malleolus (laterally) as in the left image. The right image showed content of the tarsal tunnel.

- Yellow arrow: flexor retinaculum
- White arrow: posterior tibial nerve
- Orange asterisk: posterior tibial vascular bundle
- White asterisk: posterior tibial tendon
- Yellow asterisk: medial malleolus



**Figure 2:** Hydro-dissection of the posterior tibial nerve, slightly proximal to tarsal tunnel area, performed under ultrasound guided from medial to lateral. Note that the needle (yellow arrow) pierced through muscle belly of flexor hallucis longus (orange asterisk).

- White asterisk: posterior tibialis tendon
- Yellow asterisk: medial malleolus
- White arrow: posterior tibial nerve



**Figure 3:** This was an ultrasound image at the tarsal tunnel, 3 months after the procedure. Noted that the posterior tibial nerve was less hyperechoic, with reduction in size and improve nerve gliding.

White arrow: posterior tibial nerve  
 White asterisk: posterior tibial tendon  
 Yellow asterisk: medial malleolus

neuropathy (8). Ultrasound can detect entrapment at the level of the tarsal tunnel, and causes of entrapment, such as ganglion cyst and osteophyte tendinitis, can be identified (8). Ultrasound can also detect significant muscle atrophy with or without fatty infiltration. In TTS, Fantino (8) examined 81 tarsal tunnels using ultrasound.

The most common cause of tarsal tunnel during ultrasound examination is the varicose plantar vein ( $n = 21$ ), followed by static foot posture ( $n = 20$ ). Treatment of TTS is challenging as the exact cause of TTS is often difficult to elicit. However, a detailed musculoskeletal assessment can lead to a better outcome. Patients with static foot disorder may be well suited for orthotic management, such as correction of the medial arch and strengthening of the dynamic stabilizer (4, 9). Compression due to posterior tibial nerve tenosynovitis can be managed by injection of steroids at the sheath of a posterior tibial tendon (9). A ganglion cysts can be aspirated in the presence of ganglion cysts at the tarsal tunnel (4, 9). Nerve gliding exercise of the posterior tibial nerve, along with other physiotherapeutic modalities, such as extracorporeal shock wave therapy and laser, can be beneficial (4, 9). In severe cases, neuropathic pain medication can help to reduce the pain (9). Steroid injection is effective in inflammatory diseases such as

rheumatoid arthritis (4, 9). Minimally invasive procedures, such as radiofrequency ablation, showed promising results in terms of pain management (4). Refractory TTS may benefit from tarsal tunnel decompression surgery (4).

The technique of high-resolution ultrasound-guided hydro-dissection of peripheral nerves has recently drawn the attention of the medical profession, especially in pain and musculoskeletal medicine. There is limited literature describing the role of hydro-dissection in tarsal tunnel syndrome. However, this technique has been well described in compressive neuropathy of the median nerve at the carpal tunnel (10). Hydro-dissection theory is freeing the entrap nerve release of pressure on the nervi nervorum and improves blood supply through vasa nervorum (10). The principle behind the use of Dextrose 5% (D5%) concentration during the hydro-dissection is D5% causes downregulation of TRPV1 and correct the perineural glycopenia (10).

TTS should be one of the main differential diagnosis, in patients with medial ankle neuropathic pain. Our case demonstrated that prolonged bracing could cause nerve scarring and reduced nerve gliding. Ultrasound is an emerging tool in diagnosing TTS, using the sono-



palpation technique on the nerve, sono-Tinel sign on the nerve, comparing the size of the posterior tibial nerve, visualization of nerve gliding and identify possible compressive factors such as osteophytes, ganglion cyst, or tenosynovitis in real-time events. Hydro-dissection is a minimally invasive procedure with promising outcomes and can be a potential treatment for TTS. However, a robust study is needed to recommend this technique in TTS.

### **Acknowledgment**

None

### **Conflicting interest**

The authors declare that there is no conflict of interest, and all authors participate fully in managing the patient and preparation of the manuscripts.

### **Financial support**

This is a self-funded study.

### **Informed consent**

The written consent has been taken from the patient for publication.

### **References**

1. Lau JT, Daniels TR. Tarsal tunnel syndrome: a review of the literature. *Foot Ankle Int.* 1999; 20(3):201-209.
2. Antoniadis G, Scheglmann K. Posterior tarsal tunnel syndrome: diagnosis and treatment. *Dtsch Arztebl Int.* 2008; 105(45):776-781.
3. Keck C. The tarsal-tunnel syndrome. *J Bone Joint Surg.* 1962; 44(1):180-182.
4. Vij N, Kaley HN, Robinson CL, Issa PP, Kaye AD, Viswanath O, et al. Clinical Results Following Conservative Management of Tarsal Tunnel Syndrome Compared With Surgical Treatment: A Systematic Review. *Orthop Rev (Pavia).* 2022; 14(3):37539.
5. Campbell JN, Meyer RA. Mechanisms of neuropathic pain. *Neuron.* 2006; 52(1):77-92.
6. Madani S, Doughty C. Lower extremity entrapment neuropathies. *Best Pract Res Clin Rheumatol.* 2020; 34(3):101565.
7. Frey C, Kerr R. Magnetic resonance imaging and the evaluation of tarsal tunnel syndrome. *Foot Ankle.* 1993; 14(3):159-164.
8. Fantino O. Role of ultrasound in posteromedial tarsal tunnel syndrome: 81 cases. *J Ultrasound.* 2014; 17(2):99-112.
9. Rodriguez-Merchan EC, Moracia-Ochagavia I. Tarsal tunnel syndrome: current rationale, indications and results. *EFORT Open Rev.* 2021; 6(12):1140-1147.
10. Lam KHS, Hung CY, Chiang YP, Onishi K, Su DCJ, Clark TB, et al. Ultrasound-Guided Nerve Hydrodissection for Pain Management: Rationale, Methods, Current Literature, and Theoretical Mechanisms. *J Pain Res.* 2020; 13:1957-1968.